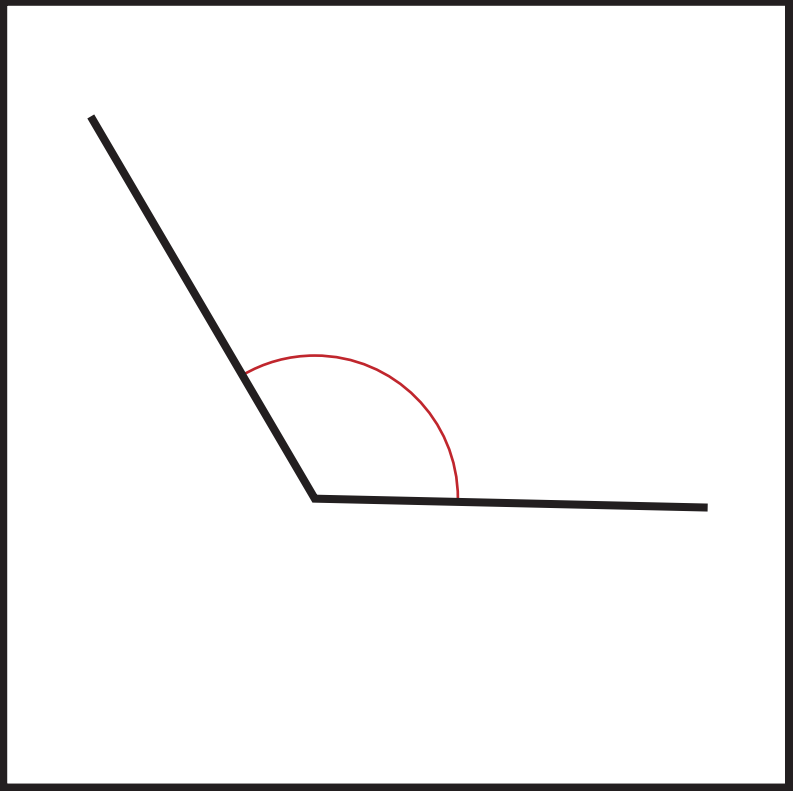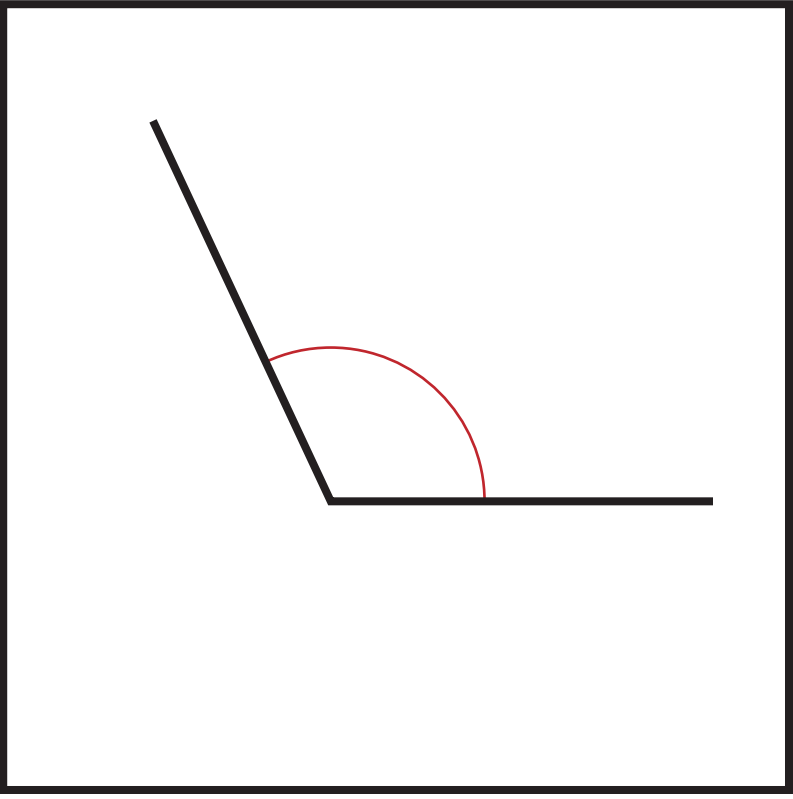
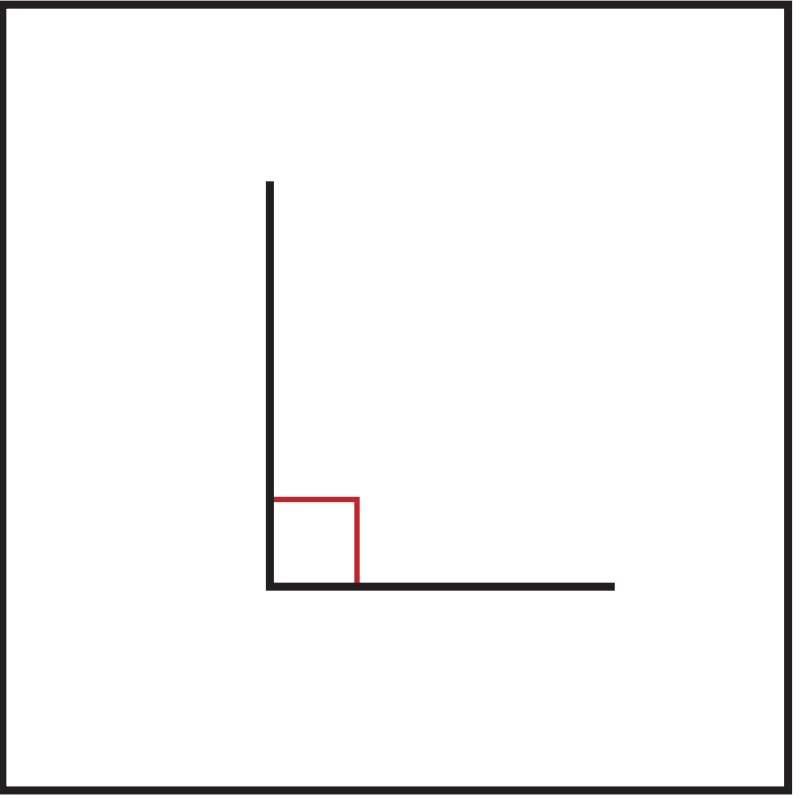
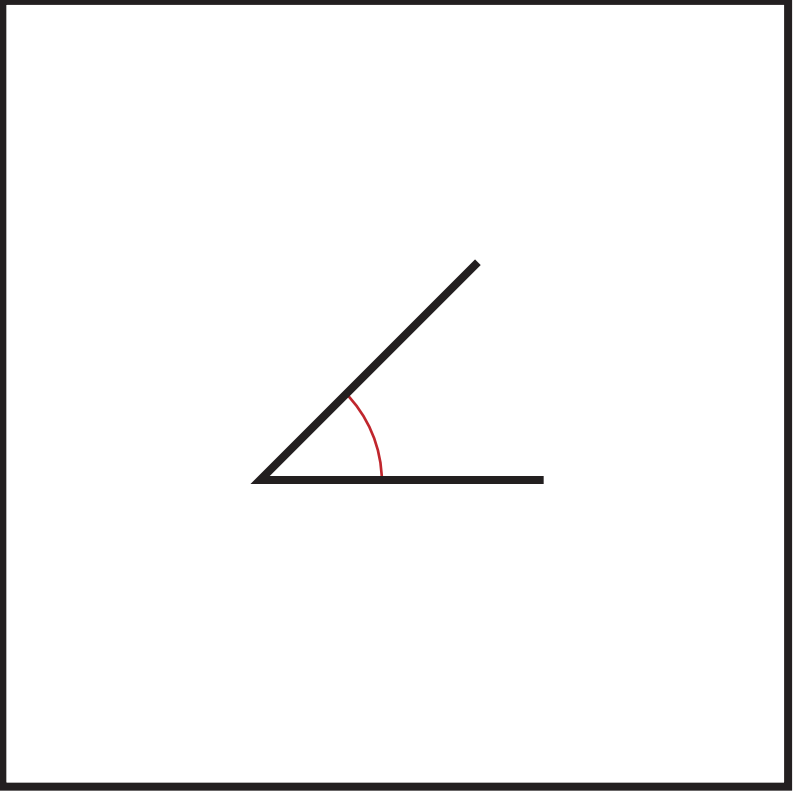


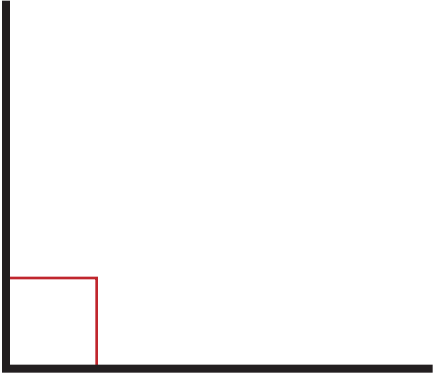Acute



Obtuse





Right

